

Steroid induced ocular complications in idiopathic nephrotic syndrome: a cross sectional single center study

Zunaira Zulfiqar¹, Fatema Lanewala², Sabeeta Khatri³, Irshad Bajeer⁴, Madiha Aziz⁵, Seema Hashmi⁶

Abstract

Objective: To screen children receiving steroids to identify ocular complications and their prevalence.

Method: The cross-sectional study was conducted at the Paediatric Nephrology and Ophthalmology departments of the Sindh Institute of Urology and Transplantation, Karachi, from May to October 2022, and comprised patients who received at least 1500mg cumulative steroid dose for a minimum of 3 months. They were screened for steroid-sensitive or steroid-resistant nephrotic syndrome. Ocular examinations, including visual acuity, intraocular pressure, slit-lamp biomicroscopy, lens examination and fundus evaluation, were performed. Data was analysed using SPSS 22.

Results: Of the 124 subjects with mean age 8.15 ± 2.03 years (range: 6-12 years), 64(51.6%) were boys. Steroid-sensitive nephrotic syndrome was present in 97(78%) cases. The mean cumulative steroid dose was 3999.31 ± 1564.22 mg. Overall, 36(29%) children developed ocular complications. Blood pressure, number of relapses and the duration of treatment were significantly associated ($p < 0.05$).

Conclusion: Refractive errors were the most frequent side effects/complication seen among children with nephrotic syndrome who received prolonged corticosteroids.

Key Words: Nephrotic syndrome, Corticosteroids, Cataract, Glaucoma, Refractive error
(JPMA 74: 315; 2024) DOI: <https://doi.org/10.47391/JPMA.10573>

Introduction

Nephrotic syndrome is the most common glomerular disease in children with relapsing and remitting course.¹ Steroids play a central role in the treatment of nephrotic syndrome, whether it is the initial episode or a relapse. Similarly, for the synergistic effect, steroids are inevitably added with other immunosuppressive medications, like cyclophosphamide, levamisole, mycophenolate mofetil and calcineurin inhibitors.²

Extended use of steroids leads to complications, like Cushingoid features, obesity, hypertension, myopathy, osteoporosis and avascular necrosis.² The reported ocular complications are keratitis, macular pigment changes, ptosis, mydriasis, atrophy of the skin of eyelid, increased intraocular pressure (IOP), and exacerbations of bacterial and viral infections.^{3,4}

Raised IOP is the most commonly studied entity in patients with steroid exposure. Its prevalence was found to be 20%, 16% and 9.1% in various studies,

.....
^{1,3-6}Department of Paediatric Nephrology, Sindh Institute of Urology and Transplantation, Karachi, Pakistan, ²Department of Ophthalmology, Sindh Institute of Urology and Transplantation, Karachi, Pakistan

Correspondence: Zunaira Zulfiqar. Email: drzunaira36@gmail.com

ORCID ID: 0009-0007-0427-6417

Submission complete: 04-08-2023

Review began: 17-09-2023

Acceptance: 08-11-2023

Review end: 08-11-2023

respectively.⁵⁻⁷ Steroids-induced ocular hypertension is caused by resistance to aqueous outflow at the level of the trabecular meshwork. Elevated IOP resulting from steroids is usually observed while receiving therapy, and, in most cases, it returns to normal once steroids are stopped.⁸

Studies have described the incidence of cataract in patients treated with systemic steroids to be 18% and 20%.^{4,7}

Despite detrimental ocular complications, including complete vision-loss, there are no recommendations of surveillance for early detection and management of these adverse effects. Studies recommended a detailed eye examination before the start of treatment.^{9,10}

The Paediatric Nephrology clinic at Sindh Institute of Urology and Transplantation (SIUT) in Karachi has observed a significant number of nephrotic children. Many of these children do not show symptoms and are unable to recognise any decline in their vision. As a result, these complications may remain unnoticed unless they undergo a proper evaluation. Detecting these serious complications early on will be beneficial in minimising additional health problems.

The current study was planned to screen children receiving steroids to identify ocular complications and their prevalence.

Patients and Methods

The cross-sectional study was conducted at Paediatric Nephrology and Ophthalmology departments of SIUT, Karachi, from May to October 2022. The sample comprised all children with steroid-sensitive nephrotic syndrome (SSNS) or steroid-resistant nephrotic syndrome (SRNS) who fulfilled the inclusion criteria of age 6-12 years, disease duration 3-24 months and being on steroid therapy for at least the preceding 2 weeks.

Children with history of ocular trauma, surgery, congenital eye abnormalities, glaucoma and systemic microvascular diseases, like diabetes, were excluded. Also excluded were patients who were unable to cooperate during ocular examination.

After taking informed written consent from the parents of the enrolled subjects, patient's demographic and clinical data along with treatment details were extracted from the hospital records. A detailed eye examination was performed by an ophthalmologist which included best corrected visual acuity (BCVA) using a Snellen chart, and IOP measurement using the air puff (Topcon CT800 Japan). Raised IOP was confirmed by applanation tonometer. The normal IOP varies with age, and some studies have proposed a formula for normal paediatric IOP; $IOP = 0.71 \times \text{age (years)} + 10$, up to the age 10 years.¹¹ After the age of 10 years, it is considered adult IOP. The cornea and anterior chamber were assessed using slit-lamp bio-microscopy (MW50D model). Lens was examined and the fundi were examined after dilatation with 1% tropicamide eye drops. Visual fields were also examined.

After receiving approval from the ethics review committee, the sample size was calculated using the

formula $n = Z^2 P (1 - P) / d^2$ as mentioned in literature.¹² In the formula, n = sample size, z (95% confidence interval [CI]) = 1.96, P = prevalence (10.3%)¹², and d = d precision (5%). The calculations were subjected to 10% attrition.

Data was analysed using SPSS 22. Continuous variables were presented as means \pm standard deviation (SD), while categorical variables were expressed as frequencies and percentages. Effect modifiers for age and gender were controlled through stratification. Post-stratification chi-square test was used for comparison. $P < 0.05$ was considered significant.

Results

Of the 124 subjects with mean age 8.15 ± 2.03 years (range: 6-12 years), 64(51.6%) were boys, and 67(54.0%) were aged 6-8 years. The mean body mass index (BMI), height, weight and body surface area (BSA) were $15.76 \pm 3.35 \text{ kg/m}^2$, $119.27 \pm 13.62 \text{ cm}$, $22.53 \pm 6.65 \text{ kg}$ and $1.01 \pm 0.5 \text{ m}^2$, respectively. SSNS was present in 97(78%) cases, while the remaining had SRNS. Renal biopsy was performed in 27(21.7%) SRNS (Table 1).

The mean relapse rate was 2.48 ± 1.05 in each patient. None of the children received cumulative dose of steroids $< 1500 \text{ mg}$, while 75(60.6%) received the highest cumulative dosage $> 3000 \text{ mg}$ during the treatment. The mean cumulative dose of steroids was $3999.31 \pm 1564.22 \text{ mg}$. The relationship between different age groups and cumulative steroid dose was assessed (Figure 1).

The mean duration of treatment was 12.46 ± 7.9 months with 54(43.5%) children receiving treatment for > 12 months.

Table-1: Baseline demographics and clinical characteristics.

Characteristics	Total (N)	Proportions %	Age in years ^r			P value
			6 to <8	8 to <10	>10	
SRNS	27	21.77	7	8	12	0.86
Blood Pressure						
Elevated	8	6.45	3	2	3	
Stage I	8	6.45	8	0	0	
Stage II	0	0	0	0	0	<0.005
Number of Relapses						
<2	78	62.9	32	20	26	
02-Apr	41	33.06	5	13	23	
02-Apr	4	3.23	0	0	1	
>6	1	0.81	0	0	1	0.002
Cumulative dose of steroids (mg)						
1500- 3000	49	39.52	17	11	21	
>3000	75	60.48	20	22	33	0.55

SSNS: Steroid-sensitive nephrotic syndrome, SRNS: Steroid-resistant nephrotic syndrome.

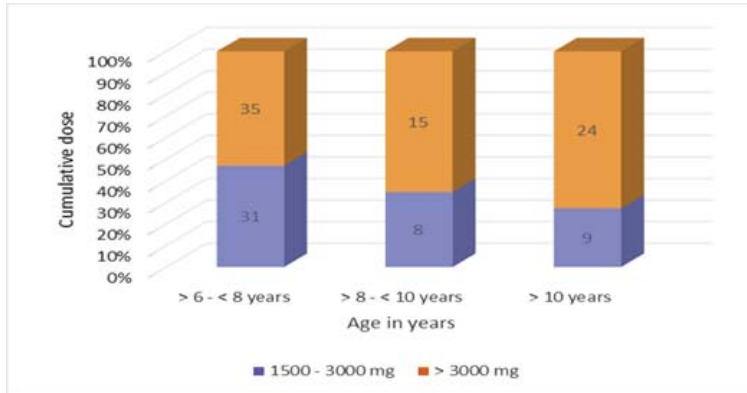


Figure-1: Relationship between different age groups and cumulative steroid dose.

frequency of complication in nephrotic syndrome

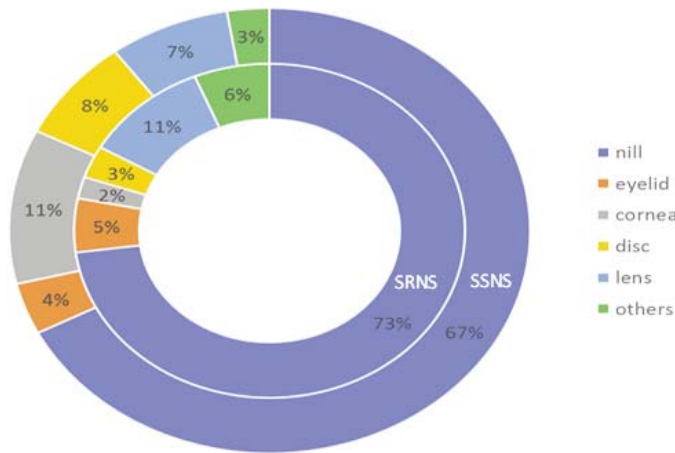


Figure-2: Frequency of complications. SSNS: Steroid-sensitive nephrotic syndrome, SRNS: Steroid-resistant nephrotic syndrome

Table-2: Ocular complications.

Complications	Frequency (n=36)	%
Refractive error	9	25
Dry eyes	7	19.44
Blepharitis	6	16.67
Glaucoma	2	5.56
Posterior sub capsular cataract	2	5.56
Conjunctivitis	1	2.78
Disc changes	1	2.78
Anisocoria	1	2.78
Estropia	1	2.78
Mild vascular	1	2.78
Mild Cortical changes	1	2.78
Myopia	1	2.78
Non-Glaucomatous Cupping	1	2.78
Pain, Blurring of vision	1	2.78
Raised Intra-ocular pressure	1	2.78

Blood pressure, number of relapses and the duration of treatment were significantly associated, with patients under treatment for <6 months being more likely to have elevated and stage I blood pressure compared to the patients treated for >6 months (p<0.005). Also, children with treatment duration >1 year had a higher prevalence of relapses (3-4) compared to the children under treatment for <12 months (p=0.002).

Overall, 36(29%) children developed ocular complications, with refractive errors being the most common 9(25%) (Table 2). The ocular complications were categorised with respect to SSNS and SRNS status (Figure 2).

There were no cases of stye or chalazion, and none of the children showed bacterial infection, keratitis, anterior chamber abnormalities, anisocoria, vitritis, or oedema, such as central serous chorioretinopathy.

Discussion

In the current study, ocular examination of 124 nephrotic children who had been on steroids for at least 2 weeks and had received a minimum of 1500mg of steroids was carried out. Ocular complications were seen in one-third of these children, with most of them having refractive errors. Ocular side-effects are an unavoidable accompaniment of steroid

use in nephrotic patients.

There was no significant difference with respect to gender, with 64(51.6%) boys and 60(49%) girls, which was also seen in an Egyptian cohort.¹³ In the current cohort, there were 9(25%) cases of error of refraction in either of the eyes, followed by blepharitis in 6(16.7%) patients. In contrast, the Egyptian cohort reported a higher incidence of refractive errors in 38(79.2%) patients, followed by blepharitis in 26(54.2%) and hypertrichosis in 25(52.1%).¹³ Conversely, an African study reported ocular complications in 80% participants, with 71% patients having hypertrichosis of the eye lashes, 56% refractive errors, 37% allergic conjunctivitis and 10% each having blepharitis and bacterial conjunctivitis.⁶ Hypertrichosis was not reported in any of the current patients, which could be reflective of ethnic variations.

In the present study, 2(5.6%) cases of glaucoma, 1(2.8%) of raised IOP in both eyes, and 2(5.6%) cases of posterior subcapsular cataract (PSCC) were also noted. An Indian study¹⁴, in contrast, found a greater percentage of patients with PSCC and raised IOP at 26.8% and 10.9% respectively. Surprisingly, ELsharkawy MM et al.¹³ did not report any case of raised IOP or PSCC despite reporting a high percentage of refractive errors in 79.2% patients. Research has proposed that fluctuating IOPs associated with steroid use stretch the globe and temporarily lengthen the axial axis, resulting in the most common refractive error of myopic astigmatism.¹⁵ However, Kyrieleis et al.¹⁶ studied this phenomenon and found no causal link. A dysfunctional immune system is attributed to both the nephrotic state and steroid treatment.⁵ Resultantly, repeated eye infection in the form of mucopurulent conjunctivitis was seen in 12(25%) patients in the study by ELsharkawy MM et al.¹³ It perhaps reflects colonisation of the conjunctival mucosa due to an immunocompromised state. In contrast, only a single case of viral conjunctivitis was reported in the current study. The mean cumulative dose of steroids for each patient in the current study was 3999.31 ± 1564.22 mg over a mean treatment duration of 12.46 ± 7.90 months. Gaur et al.¹⁴ reported an accumulative corticosteroid dose of 338.9mg/kg, but the median duration of follow-up was longer at 4.95 years. Similarly, ELsharkawy MM et al.¹³ documented a cumulative steroid dose use of 7250 ± 1110 mg over a mean time period of 2.6 ± 1.6 years. Literature suggests that systemic steroids gain access to the ocular tissues via the blood stream and affect apoptosis, cell membrane stability, proteolysis and phagocytosis of extracellular matrix contributing to the development of various ocular and other complications, especially with long-term use.¹⁷⁻¹⁹ A longer treatment duration with greater dose of steroids could explain the greater frequency of complications in these studies¹⁷⁻¹⁹.

In the current study, presence of hypertension was statistically significant in children under treatment for <6 months. This could be attributed to the oedematous state at the onset of disease or a relapse.²⁰ A family history of essential hypertension was also found contributory by Keshri et al. but this is yet to be explored in Pakistani children.²¹

Nearly one-third of the current patients developed 3-4 episodes of relapse and this was significantly associated with a longer duration of treatment. As reported by Williams et al.²² up to 80% of children with steroid sensitive nephrotic syndrome experience at least one relapse, and more than half of these children go on to developing a frequent relapsing and/or steroid-

dependent course as was also seen in the current study. This would necessitate frequent exposure to corticosteroids and the side effects that come with it.

The current study has its limitations. It was a cross-sectional study in which patients could not be serially assessed for development or resolution of ocular complications and outcomes. Moreover, it was a single-centre study which does not represent the nephrotic population of Pakistani children at large. Multi-centre studies are recommended to assess the ophthalmological complications associated with prolonged steroid use.

Conclusion

Ocular complications were noted in one-third of the nephrotic syndrome patients studied, with a predominance of refractive errors of the eyes. Regular and timely assessment of children on steroids can help prevent and manage ocular complications for an improved quality of life

Disclaimer: None.

Conflict of Interest: None.

Source of Funding: None.

References

1. Robson WL, Leung AK. Nephrotic syndrome in childhood. *Adv Pediatr.* 1993; 40:287-323.
2. Trautmann A, Boyer O, Hodson E, Bagga A, Gipson DS, Samuel S, et al. IPNA clinical practice recommendations for the diagnosis and management of children with steroid-sensitive nephrotic syndrome. *Pediatr Nephrol.* 2023; 38:877919. doi: 10.1007/s00467-022-05739-3.
3. Gheissari A, Attarzadeh H, Sharif H, Pourhossein M, Merrikhi A. Steroid dependent and independent ocular findings in Iranian children with nephrotic syndrome. *Int J Prev Med.* 2011; 2:264-8.
4. Chaudhury GN, Khandaker T, Ferdous T, Chowdhury RA, Afroz S, Hanif M. Ocular and extra-ocular complications following longterm steroid consumption in children with idiopathic nephrotic syndrome. *BIRDEM Med J.* 2021; 11:7-10.
5. Hayasaka Y, Hayasaka S, Matsukura H. Ocular findings in Japanese children with nephrotic syndrome receiving prolonged corticosteroid therapy. *Ophthalmologica.* 2006; 220:181-5. doi: 10.1159/000091762.
6. Nakubulwa F, Lusobya RC, Batte A, Ssuna B, Nakanjako D, Nakiyingi L, et al. prevalence and predictors of ocular complications among children undergoing nephrotic syndrome treatment in a resource-limited setting. *BMC ophthalmology.* 2021; 21:1-7. doi: 10.1186/s12886-021-01817-6.
7. Hariharan R, Krishnamurthy S, Kaliaperumal S, Karunakar P, Deepthi B. Incidence and predictive risk factors for ophthalmological complications in children with nephrotic syndrome receiving longterm oral corticosteroids: a cohort study. *Paediatr Int Child Health.* 2021; 41:199-205. doi: 10.1080/20469047.2021.1983315.
8. Roberti G, Oddone F, Agnifili L, Katsanos A, Michelessi M, Mastropasqua L, et al. Steroid-induced glaucoma: Epidemiology, pathophysiology, and clinical management. *Surv Ophthalmol.* 2020; 65:458-72. doi: 10.1016/j.survophthal.2020.01.002.

9. Sato M, Ishikura K, Ando T, Kikunaga K, Terano C, Hamada R, et al. Prognosis and acute complications at the first onset of idiopathic nephrotic syndrome in children: a nationwide survey in Japan (JP-SHINE study). *Nephrol Dial Transplant.* 2021; 36:475-81. doi: 10.1093/ndt/gfz185.
10. Agrawal V, Devpura K, Mishra L, Agarwal S. Study on steroid induced ocular findings in children with Nephrotic syndrome. *Journal of clinical and diagnostic research: J Clin Diagn Res.* 2017; 11:SC05-6. doi: 10.7860/JCDR/2017/24694.9334.
11. Bresson-Dumont H. Intraocular pressure measurement in children. *French J Ophthalmol.* 2009; 32:176-81. doi: 10.1016/j.jfo.2009.03.008.
12. Ng JS, Wong W, Law RW, Hui J, Wong EN, Lam DS. Ocular complications of paediatric patients with nephrotic syndrome. *Clin Exp Ophthalmol.* 2001; 29:239-43. doi: 10.1046/j.1442-9071.2001.00426.x.
13. ELsharkawy MM, Abdelrahman HM, Omar KA, Deiaeldin YA. Assessment of Ocular Manifestations in Children with Nephrotic Syndrome during steroid Treatment. *Egyptian J Hosp Med.* 2023; 91:4672-8.
14. Gaur S, Joseph M, Nityanandam S, Subramanian S, Koshy AS, Vasudevan A, et al. (2014): Ocular Complications in Children with Nephrotic Syndrome on Long Term Oral Steroids. *Indian J Pediatr.* 2014; 81:680-3. doi: 10.1007/s12098-014-1338-2.
15. Barry A, McNulty MT, Jia X, Gupta Y, Debiec H, Luo Y et al. Multi-population genome-wide association study implicates immune and nonimmune factors in pediatric steroid-sensitive nephrotic syndrome. *Nat Commun.* 2023; 14:2481. doi: 10.1038/s41467-02337985-w.
16. Kyrieleis HA, Löwik MM, Pronk I, Cruysberg HR, Kremer JA, Oyen WJ, et al. Long-term outcome of biopsy-proven, frequently relapsing minimal-change nephrotic syndrome in children. *Clin J Am Soc Nephrol.* 2009; 4:1593-600. doi: 10.2215/CJN.05691108.
17. Jobling AI, Augusteyn RC. What causes steroid cataracts? A review of steroid-induced posterior subcapsular cataracts. *Clin Exp Optom.* 2002; 85:61-75. doi: 10.1111/j.1444-0938.2002.tb03011.x.
18. Jones R, Rhee DJ. Corticosteroid-induced ocular hypertension and glaucoma: a brief review and update of the literature. *Curr Opin Ophthalmol.* 2006; 17:163-7. doi: 10.1097/01.icu.0000193079.55240.18.
19. Razeghinejad MR, Katz LJ. Steroid-induced iatrogenic Glaucoma. *Ophthalmic Res.* 2012; 47:66-80. doi: 10.1159/000328630.
20. Shatat IF, Becton LJ, Woroniecki RP. Hypertension in Childhood Nephrotic Syndrome. *Front Pediatr.* 2019; 7:287. doi: 10.3389/fped.2019.00287.
21. Keshri S, Sharma S, Agrawal N, Bansal S, Guilliani BP, Aggrawal KC. Hypertension and its severity in children with steroid sensitive nephrotic syndrome during remission. *Clin Exp Nephrol.* 2018; 22:1157-62. doi: 10.1007/s10157-018-1565-3.
22. Williams E, Gbadegesin A. Steroid Regimen for Children with Nephrotic Syndrome Relapse. *Clin J Am Soc Nephrol. CJASN.* 2021; 16:179-81. doi: 10.2215/CJN.19201220.

Author's Contributions

ZZ: Literature search, drafting and analysis.

FL: Ophthalmologic examination of children, critical review, analysis and drafting.

SK, IB and MA: Critical review, analysis and drafting.

SH: Critical review, analysis and conception of design