

## Evaluation of gingival biotype and recession following non-surgical periodontal treatment using 3-dimensional scan methods

Ali Sadiq<sup>1</sup>, Jacopo Buti<sup>2</sup>, Kevin Seymour<sup>3</sup>, Farhan Raza Khan<sup>4</sup>

### Abstract

The study evaluated the position of gingival margins in anterior teeth using clinical and 3-dimensional (3D) optical scanning method among patients subjected to non-surgical periodontal treatment (NSPT). A single arm, longitudinal study was undertaken at the Archway Dental Center, University of Manchester, UK. History and clinical examination were done. Gingival recession, attachment loss (AL), and periodontal probing depth (PD) were recorded at baseline and 12-weeks follow-up. NSPT was done using hand and ultrasonic instruments. Impressions were made, the resultant gypsum models were scanned to generate 3D images. The change in the gingival level and thickness of facial gingiva were assessed. Out of eight patients recruited, three were lost to follow up. The 3D scan showed a poor correlation with the clinical assessment of gingival recession in anterior teeth following NSPT ( $r = -0.0089$ ). Recession did not improve after NSPT ( $p \leq 0.20$ ).

**Keywords:** Gingival recession; biotype; probing depth; attachment loss; non-surgical periodontal treatment.

**DOI:** <https://doi.org/10.47391/JPMA.6366>

**Submission completion date:** 19-09-2022

**Acceptance date:** 01-04-2023

### Introduction

Some degree of gingival recession is inevitable after surgical and non-surgical periodontal treatment.<sup>1</sup> Gingival biotype and baseline probing pocket depth are the important determinants of gingival recession in such treatment.<sup>2,3</sup> Recession of the gingival margins exposes the root surface that could lead to hypersensitivity in the dentine. In anterior teeth, gingival recession causes an additional problem of compromised aesthetics.

It's not uncommon for researchers to overestimate or underestimate the extent and severity of periodontal disease. This stems from an inherent variability in using periodontal probe for recording the periodontal data.<sup>4</sup> The

<sup>1,4</sup>Department of Surgery, Aga Khan University, Karachi, Pakistan;

<sup>2</sup>Department of Periodontology, University College London, Eastman Dental Institute, London, England; <sup>3</sup>The University of Manchester, School of Dentistry, Manchester, England.

**Correspondence:** Ali Sadiq. e-mail: [dr.alisadiq@gmail.com](mailto:dr.alisadiq@gmail.com)

ORCID ID. 0000-0003-3336-3513

accuracy and reproducibility do not only vary between the assessors but also within the same subjects at different points in time. This compromises the quality of periodontal data, especially the measurement of the soft tissue thickness (gingival biotype) and gingival recession. The use of 3D scanning has been documented for volumetric changes in the gingiva.<sup>5</sup>

The objective of the study was to compare the position of the free gingival margin in the maxillary and mandibular anterior teeth assessed using clinical versus 3D scanning method among patients subjected to NSPT.

### Methods and Results

A single arm, longitudinal study was conducted from August 2013 to July 2014 at the Archway Dental Practice, Manchester, UK. The study protocol was approved by NRES Committee 2 (ID#13/NM/0545). Written informed consent from the participants was obtained in English. The study conformed to the NHS guidelines on research.

The study participants were males and females, more than 18 years of age, presenting with generalised periodontitis but sustaining at least one mid-buccal or inter-proximal site around the anterior teeth (from canine to canine) with probing pocket depth  $\geq 5$ mm. Participants having dental prosthesis or prosthesis in the anterior teeth, or with history of orthodontics were excluded. Physically or mentally challenged subjects who could not maintain their oral hygiene were also excluded.

To calculate the sample size, a study<sup>1</sup> which evaluated changes in the gingival recession following NSPT on 82 patients with initial probing pocket depth of 5-6mm was used. They have reported 0.27mm ( $\pm 0.06$ mm) change in gingival recession at three months follow-up. Keeping two-sided significance level at 0.05, power of the study at 0.80, and difference in recession of 0.50mm  $\pm$  0.54mm, at least 12 participants were needed for the present study. Considering a potential drop-out, the sample size was inflated to reach a final number of 15 patients.

History, clinical examination, investigations, and impression making of the selected participants were done at baseline and at 12 weeks post NSPT. Patients' level factors recorded in the study were: presence of diabetes, history of smoking,

alcohol consumption, family history of gingival disease, oral hygiene practices, full mouth plaque, and bleeding scores, etc. Teeth level factors were malposition of anterior teeth, and visual observation of gingival biotype (classified as thin, normal, and thick), etc. Site level factors included probing depth, bleeding on probing, and attachment loss. Periodontal charting was carried out on six points using William's probe.

Dental impressions were made using fast setting alginate (Fidelity 25, UK). These were poured in dental stone (SHERAPREMIUM, Germany) to form the study casts. All models (baseline and follow-ups) were scanned using a 3D scan unit (Maestro MDS400, Italy). Each follow-up scan was superimposed by its corresponding baseline scan using Ortho-Analyser software (3shape, Denmark). The scanner and software were used to generate 3D images of the cast. The same software was used to record the change in the gingival margin position. For superimposition of each pair of models, pre-identified fixed reference points were employed (Figure).

The following measurements were recorded from the 3D scan: gingival biotype, level of gingival margin at baseline, and gingival recession at 12-week follow-up.

Descriptive statistics (mean and SD) were computed for continuous variables. For categorical variables, proportions were reported. Paired t test was applied to compare changes in the gingival recession, probing depth, and attachment loss from baseline to 12-week follow-up. Pearson correlation test was applied to correlate soft tissue changes recorded clinically with those recorded digitally with 3D scan. A p-value of <0.05 was taken as statistically significant.

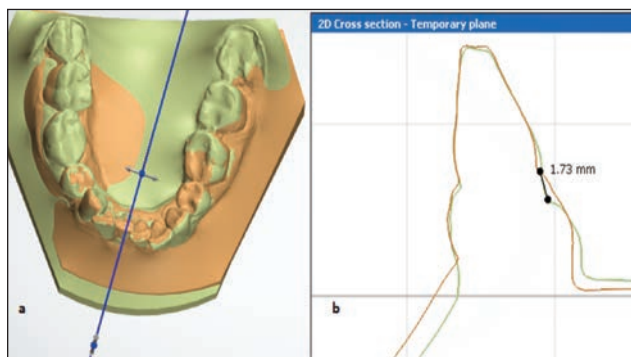
A total of 15 patients were required for the study. However, due to time restraints only eight patients who fulfilled the study criteria were recruited. Of these, three patients dropped out for personal reasons. As a result, data of five participants who were retained till the 12-week follow-up is reported here. The descriptive statistics are shown in Table 1.

The mean age of the participants was  $48.6 \pm 5.3$  years. At baseline, the mean gingival recession, PD and AL were  $0.49 \pm 0.96$  mm,  $3.25 \pm 1.82$  mm and  $3.73 \pm 2.05$  mm, respectively.

The gingival biotype clinically classified as thin and normal were observed on 3D scan to have thickness of  $0.7 \pm 0.26$  mm and  $0.8 \pm 0.24$  mm, respectively. The gingival tissues clinically classified as thick, demonstrated thickness of  $0.80 \pm 0.30$  mm on the 3D scan. Figure.

**Table-1:** Patients and sites baseline characteristics.

Variables	n (%)
Females	4/5 (80)
Age range (years)	41 to 57
Non-smokers (%)	2/5 (40)
Smokers (%) [>5 cigarettes/day]	3/5 (60)
Full mouth plaque scores (%)	26.4 (11.3)
Full mouth bleeding scores (%)	21.4 (16.9)
Thin biotype	3/5 (60)
Normal biotype	1/5 (20)
Thick biotype	1/5 (20)
<b>Tooth position</b>	
Upper incisors	20 (33.3)
Upper canines	10 (16.7)
Lower incisors	20 (33.3)
Lower canines	10 (16.7)
<b>Degree of Mobility</b>	
Mobility grade 1 (%)	-
Mobility grade 2 (%)	-



**Figure:** Measurement of gingival margins using 3D scan.

a) A 3D scan cross-sectioned at mid buccal/lingual level of the tooth

b) A 2D cross section shows the gingival recession of 1.73 mm at 12 weeks follow-up.

**Table-2:** Patients and sites baseline characteristics.

Timepoint	Recession (mm) Mean±SD	PD (mm) Mean±SD	AL (mm) Mean±SD
<b>Baseline</b>	0.49±0.96	3.25±1.82	3.73±2.05
<b>12 weeks follow-up</b>	0.54±0.97	2.58±1.23	3.11±1.58
<b>Difference (SE)</b>	0.05±0.04	-0.67±0.08	-0.62±0.09
<b>p-value</b>	0.20	0.0003*	<0.001*

Paired t test was applied; \*Statistically significant difference.

Mean changes in periodontal parameters from the baseline to 12-week follow-up post NSPT are shown in Table 2. It was observed that recession was not markedly improved (p-value 0.20). However, statistically significant mean difference was detected for the PD ( $-0.67 \pm 0.08$  mm;  $p=0.0003$ ) and AL ( $-0.62 \pm 0.09$  mm;  $p \leq 0.0001$ ).

## Discussion

The 3D scanning of gingival tissues is an innovative approach to evaluate post NSPT recession. This method was compared with the standard clinical evaluation

method for the determination of biotype as well. An extremely poor correlation ( $r=-0.0089$ ) between clinical and 3D scan methods disproves the utility of 3D method for this purpose. The 3D method could not decipher a difference between normal and thick gingival biotype.

The inferior results of 3D scan could be attributed to imperfect superimposition of the study models. The precision of the scanner itself could be responsible for low accuracy of images. The 3D scanner used in the present study had an accuracy of 10 microns. Although the software employed in the study was compatible with the scanner, the superimposed images still exhibited inaccuracies. The vertical readings were affected due to imperfect superimposition of the images but the horizontal readings could still be considered accurate because it was calibrated by cross-sectioning of the baseline model.

A mean reduction in PD of 0.67mm was recorded from the baseline to 12-week follow-up. Literature suggests that the sites with deeper pockets (>4mm) showed greater reduction compared to the shallow pockets (<3mm).<sup>6</sup> The present study also included sites with PD > 5mm whereas the previous studies<sup>7,8</sup> have mainly reported shallow pockets (<4mm) only. Similarly, greater mean gain in the attachment level (-0.62 mm) was observed in the present study compared to the previous studies.<sup>7,8</sup> However, the mean change in the gingival recession in the present study is in agreement with the previous studies.

Clinical measurement and 3D assessment were performed to quantify vertical change in the gingival margin. No correlation between the two methods was detected. The 3D scanning technique is sensitive as it has some inherent errors occurring at various steps, such as impression taking, pouring of the impression, scanning of the model, and use of software in generating digital 3D image. In addition, it increases the cost of the treatment, requires dental laboratory to be equipped with high quality scanner and technicians capable of operating the software and the scanner. Considering all these factors, its utility in routine clinical practice seems challenging. However, recent studies<sup>9,10</sup> have shown promising results of digital scanning of gingival soft tissues changes after periodontal surgery.

The present study can best be considered a pilot investigation aimed to explore an innovative 3D digital method to evaluate gingival recession and biotype. With data of five participants only, the results cannot be generalised and extrapolated widely. The utility of 3D scanning for the evaluation of gingival margins should be validated with further research.

## Conclusion

No correlation was found between the clinical and 3D scan methods for the evaluation of gingival recession. The 3D scan method could not discriminate between gingival biotypes.

**Disclaimer:** We sincerely apologize for the unfortunate delay in submitting our article for publication, which was primarily due to academic and professional commitments. These obligations intermittently affected the time available for the writing process. Nevertheless, we want to assure our readers that during this extended period, we have been dedicatedly updating the references and discussion section to ensure the accuracy and relevance of the work.

**Conflict of interest:** None.

**Funding Sources:** None.

## References

1. Kaldahl WB, Kalkwarf KL, Patil KD, Molvar MP. Evaluation of gingival suppuration and supragingival plaque following four modalities of periodontal therapy. *J Clin Periodontol* 1990; 17: 642-9.
2. Lindhe J, Socransky SS, Nyman S, Westfelt E. Dimensional alteration of the periodontal tissues following therapy. *Int J Periodontics Restorative Dent* 1987; 7: 9-21.
3. Kim DM, Bassir SH, Nguyen TT. Effect of gingival phenotype on the maintenance of periodontal health: An American Academy of Periodontology best evidence review. *J Periodontol* 2020; 91: 311-38.
4. Chu Y, Ouyang X. Accuracy of partial-mouth examination protocols for extent and severity estimates of periodontitis: a study in a Chinese population with chronic periodontitis. *J Periodontol* 2015; 86: 406-17.
5. Kim YS, Park JS, Jang YH, Son JH, Kim WK, Lee YK, et al. Accuracy of periodontal probe visibility in the assessment of gingival thickness. *J Periodontal Implant Sci.* 2021; 51: 30-9.
6. Ainamo J, Bay I. Problems and proposals for recording gingivitis and plaque. *Int Dent J* 1975; 25: 229-35.
7. Lehmann KM, Kasaj A, Ross A, Kämmerer PW, Wagner W, Scheller H. A new method for volumetric evaluation of gingival recessions: a feasibility study. *J Periodontol* 2012; 83: 50-4.
8. Greenberg J, Laster L, Listgarten MA. Transgingival probing as a potential estimator of alveolar bone level. *J Periodontol* 1976; 47: 514-7.
9. Rebele SF, Zuhr O, Schneider D, Jung RE, Hürzeler MB. Tunnel technique with connective tissue graft versus coronally advanced flap with enamel matrix derivative for root coverage: a RCT using 3D digital measuring methods. Part II. Volumetric studies on healing dynamics and gingival dimensions. *J Clin Periodontol* 2014; 41: 593-603.
10. Zuhr O, Akakpo D, Eickholz P, Vach K, Hürzeler MB, Petsos H; Research group for oral soft tissue biology & wound healing. Tunnel technique with connective tissue graft versus coronally advanced flap with enamel matrix derivate for root coverage: five-year results of an RCT using 3D digital measurement technology for volumetric comparison of soft tissue changes. *J Clin Periodontol* 2021;48: 949-61.