

## An improvised approach for regaining mouth opening and managing tooth wear in oral sub-mucous fibrosis

Farhan Raza Khan,<sup>1</sup> Muhammad Rizwan Nazeer<sup>2</sup>

### Abstract

This case report demonstrates the full mouth prosthetic rehabilitation of a patient with generalised compensated tooth wear and oral sub-mucous fibrosis (OSMF). A 50-year-old female with advanced tooth wear and concomitant OSMF presented to the clinic. She was managed in a sequential manner using an occlusal splint, extractions of hopeless teeth, root canal treatment of strategically important teeth, surgical crown lengthening of abutment teeth, and dental implants to replace missing dentition, followed by crown and bridgework to rehabilitate the dentition. All procedures were done on the principles of re-organised occlusal intervention. The outcome was a functional dentition with an aesthetic smile and a satisfied patient. The regaining of mouth opening among OSMF subjects is a challenge. The usual management is prescribing muscle stretching exercises, drugs, or surgery. In the present case, we managed to achieve significant improvement in mouth opening with occlusal splints. The use of such occlusal orthotics has never been reported.

**Keywords:** Occlusal splints; orthotic devices; oral sub-mucous fibrosis; tooth wear.

**DOI:** 10.47391/JPMA.6509

**Submission completion date:** 03-06-2022

**Acceptance date:** 07-01-2023

### Introduction

Tooth wear is defined as the loss of tooth substance by physical, mechanical, or chemical means other than dental caries or trauma.<sup>1</sup> The causative factors for tooth wear can be broadly classified into abrasion, attrition, erosion, and abfraction.<sup>2,3</sup> The impact of tooth wear on the vertical dimension of occlusion can be either compensated or non-compensated.<sup>4</sup> Tooth wear is either managed by conforming to the existing occlusal scheme or by reorganising the occlusion at a new vertical height.

.....  
<sup>1</sup>Department of Operative Dentistry and Endodontics, Aga Khan University Hospital, Karachi, Pakistan, <sup>2</sup>Department of Operative Dentistry and Endodontics, Bahria University Medical and Dental College, Karachi, Pakistan.

**Correspondence:** Farhan Raza Khan. Email: farhan.raza@aku.edu

**ORCID ID.** 0000-0002-5650-6268

For reorganised occlusion treatment, a hard Michigan splint (occlusal orthotic device) is given to the patient for four to six weeks to get his or her temporomandibular joint (TMJ) accustomed to the new vertical dimension of occlusion. The reorganised occlusal treatment involves a series of steps, all of which require time, clinicians' expertise, and patient cooperation.<sup>5</sup>

Oral sub-mucous fibrosis (OSMF) is a benign neoplastic lesion of the oral cavity which is characterised by fibrosis of the lamina propria and formation of fibrous bands in the buccal mucosa. There is a reduction in the mouth opening, white, leathery appearance of oral mucosa, burning sensation on consuming spicy foods, and other dental or periodontal problems resulting from inability to maintain oral hygiene owing to limited mouth opening.<sup>6</sup> The most common aetiological factor for its development is areca nut/betel quid chewing. For this reason, OSMF is mainly seen in people of India, Pakistan, and Bangladesh where betel quid chewing is a normal cultural practice.<sup>7,8</sup> Carrying out dental work in such a reduced mouth opening is sometimes impossible. Thus, it is only managed with a conservative approach of prescribing mouth opening exercises, regular oral hygiene maintenance, and supplementation of micronutrients.<sup>9</sup>

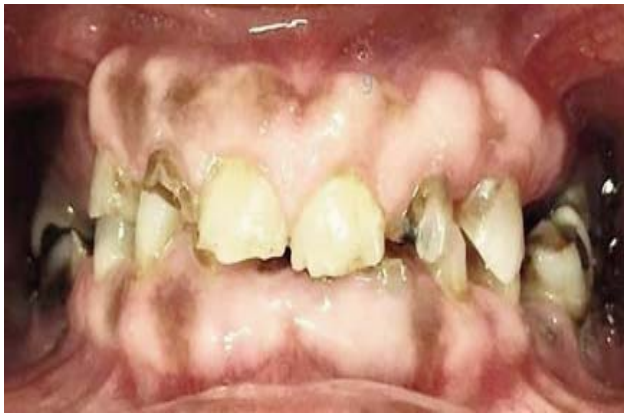Presence of advanced tooth wear gets complicated if the subject is concomitantly affected with OSMF, as this poses another challenge of not only reconstructing the bite but carrying out dental work in limited mouth opening which is a mammoth task. The present case report elucidates the stage-by-stage full mouth rehabilitation of a patient with generalised compensated tooth wear and OSMF.

### Clinical Presentation

A 50-year-old female visited the dental clinics of Aga Khan University Hospital Karachi, Pakistan, in December 2019 with the chief complaint of "pain in the left upper tooth for two weeks along with off and on discomfort in multiple broken down roots for several months". The patient was also unhappy with the appearance of her teeth and had difficulty in chewing from both sides. The patient expressed her interest in getting fixed replacement of missing teeth.

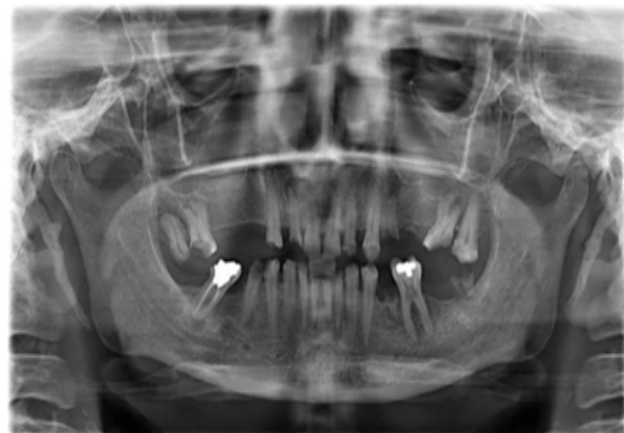The patient was otherwise healthy with no known comorbidities or allergies. She had a history of areca nut

chewing for more than 15 years. She didn't report any parafunctional habits. On extra oral examination, limited mouth opening of approximately 18mm was recorded. TMJ examination revealed no tenderness, crepitus, or any deviation on opening or closing. The vertical dimension both at rest and in occlusion were measured which revealed a difference of 3-4mm. On intraoral examination, the patient had poor oral hygiene with multiple decayed teeth. Thick white bands were palpable on the bilateral buccal mucosa, revealing moderate OSMF. Generalised tooth wear was observed with multiple occlusal facets along with uneven occlusal plane (Figure 1).



**Figure-1:** Preoperative clinical presentation.

The panoramic radiograph showed multiple carious, broken-down roots and missing teeth along with some restored teeth (Figure 2). The diagnostic casts revealed severe attrition and an uneven occlusal plane. Her problem list comprised advanced tooth wear (compensated), loss of occlusal vertical dimension, moderate oral sub-mucous fibrosis, and missing a substantial number of teeth. After discussing the



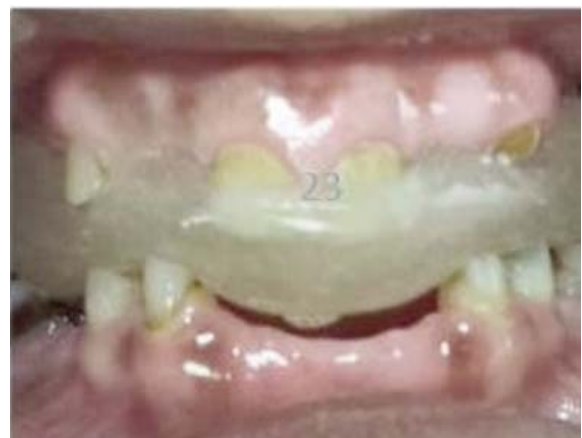**Figure-2:** Preoperative panoramic view.

treatment plan and obtaining written informed consent, following steps were undertaken:

Extraction of hopeless teeth (FDA #18, 17, 12, 22, 24, 25, 26, 27, 35, 32, 31, 41, and 45). Elective endodontic treatment of teeth (as substantial tooth preparation was warranted for the crown bridgework) that could serve as prosthesis abutment. These included (FDA# 13, 11, 21, 23, 36, 34, 33, 43, and 44 with endodontic retreatment in # 46. The core build-up was carried out using composite resin (Filtek™ Bulk Fill Posterior Restorative, 3M ESPE). Fibre reinforced post was placed into tooth FDA# 23. Restoration of the lost vertical dimension and correction of the occlusal plane was carried out. Restoration of the masticatory function and aesthetics using temporary acrylic fixed bridge followed by permanent metal-ceramic fixed bridge was done.

Two Zimmer TSV implants were surgically placed in the right and left upper first premolar regions at FDA # 14 and 24 (3.7mm × 11.5mm) and two more implants were placed in the molar regions at FDA # 26 and 36 (4.8mm x 10mm). The primary stability of >30N was achieved on all implants. Cover screws were placed on the implants and surgical flaps were sutured to follow the submerged protocol.

The impressions were made along with a bite registration recorded in centric relation. The casts were mounted on a semi-adjustable articulator at an increased vertical dimension of 4mm. A hard clear acrylic, resin-based, tooth-borne occlusal orthotic (modified Michigan splint) was fabricated (Figure 3). The adaptation of the patient to an increased vertical dimension was evaluated in subsequent weekly follow-ups for 10-weeks. The patient reported mild discomfort initially after delivery of the occlusal orthotic for 10 days.



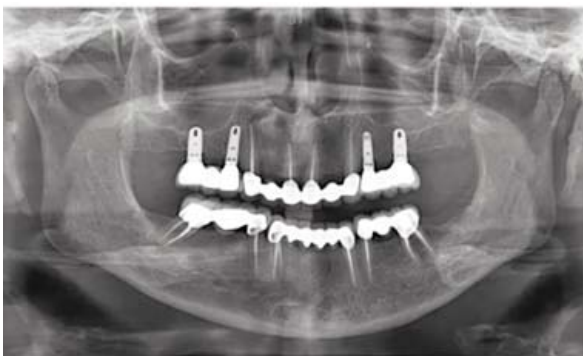
**Figure-3:** With Michigan splint in position.

Later, no muscle tenderness or discomfort in temporomandibular joint was noted. An interesting observation in this case was that the mouth opening significantly improved (from 18mm to >36mm) in 10 weeks. This made the subsequent prosthetic work easy.

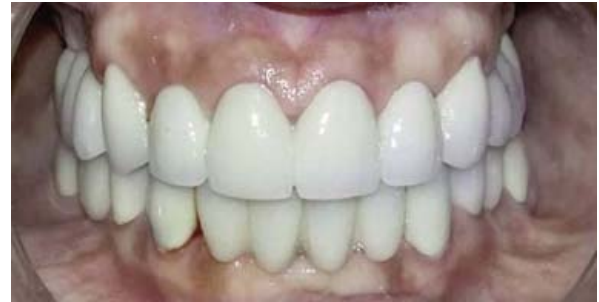All the natural abutment teeth were prepared for the fixed bridge. A provisional resin-based (Integrity, Temporary crown bridge material, Dentsply, USA) bridge was fabricated using a vacuum formed stent directly in the patient's mouth at the new vertical height. However, the implant abutments were kept screw retained. The occlusion was adjusted, and the teeth-borne fixed bridge was placed temporarily with zinc oxide non-eugenol cement (Freegenol, GC Dental, USA).

After two weeks, the temporary bridge was removed and a final impression with putty-wash polyvinylsiloxane (Aquasil, Ultra Monophase, Dentsply, USA) was made. Provisional restorations were again secured in place for an interim period. The metal casting trial (ME alloy, Dentsply, USA) was followed by a porcelain (CERAMCO, Dentsply, USA) bisque-bake trial. After all the necessary occlusal adjustments were made, the bridges were glazed, and aesthetics was approved by the patient. The final occlusal scheme was group-function bilaterally on lateral excursions and even guidance on all anterior teeth during protrusive movements. The fixed bridges were finally cemented with glass ionomer-based cement [GC (Gold Label) Luting and Lining Cement, Tokyo, Japan]. The implant bridges were connected using screw-retained mechanism.

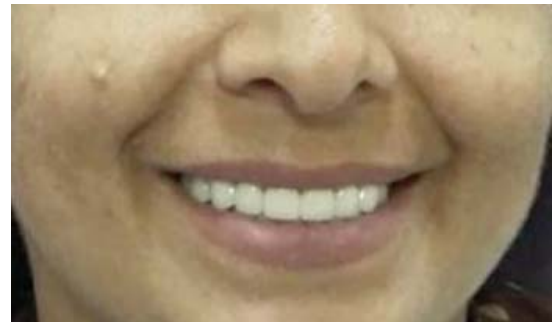Figure 4 shows the post treatment panoramic radiograph displaying satisfactory outcomes. Figures 5 and 6 show six weeks and one year follow-up clinical pictures of frontal and smile views exhibiting predictable soft tissue aesthetics. The patient exhibited an excellent oral hygiene. Her mouth opening was intact at 36mm with no



**Figure-4:** Postoperative panoramic view.



**Figure-5:** Postoperative clinical image.



**Figure-6:** Twelve-month follow-up image.

craze lines or porcelain chipping off at all. SCARE guideline was followed for composing the case report.

## Discussion

In the present case, we opted for a conservative method of employing an occlusal orthotic (modified Michigan stabilization splint).<sup>10-12</sup> The occlusal orthotic was well tolerated by the patient and the desired results were achieved. However, unlike other reported cases, presence of moderate OSMF had posed a great challenge in our case. A significant increase in the mouth opening (from 18mm to >36mm) was recorded in the present case.

Although the exact mechanism by which the occlusal orthotic improved the mouth opening is unknown, it can be speculated that the orthotic applied constant interocclusal force that counteracted the fibrotic bands responsible for contracture of the connective tissues in the sub-mucosal layer. The other reason for improvement in mouth opening by an orthotic could be elimination of the posterior interference during protrusive movement.<sup>13</sup> The literature is scarce on reporting this observation. However, the only case<sup>14</sup> which has showed a similar finding was seen in India where the clinicians employed an occlusal orthotic appliance and gained a significant improvement in mouth opening of an advanced case of OSMF. However, their patient was completely edentulous and the occlusal orthotic was employed immediately after surgery done under general anaesthesia.

The other approaches to gain mouth opening are muscle

stretching exercises (using mouth gags or interposing spatulas between opposing teeth), use of corticosteroids such as Hydrocortisone, Dexamethasone, Triamcinolone, or a combination of drugs, peripheral vasodilators such as Pentoxifylline or Nylidrin, enzymes such as Hyaluronidase, Collagenase, or Chymotrypsin, and antioxidants such as Vitamin A, C, E and Beta-Carotene etc., herbal extracts such as Aloe Vera and Turmeric derivatives, etc.<sup>15</sup> Other orthotic devices with innovative designs have also been suggested for this purpose.<sup>16</sup> Surgery is done in advanced cases where mouth opening is severely restricted. These include nasolabial flaps, tongue flaps, temporalis fascia transfer and buccal fat pad, temporalis myotomy or even coronoidectomy.<sup>17</sup> However, there is no single approach which can be used as the definitive treatment modality to cure OSMF.<sup>18</sup>

We originally advised the occlusal orthotic for managing tooth wear. However, a substantial improvement in mouth opening (36mm) came up as an incidental but fortunate finding. This can be attributed to an excellent patient compliance of using the occlusal orthotic that was monitored with regular follow-ups. To our knowledge, no case has been reported in the literature on management of tooth wear affected concomitantly with OSMF. Occlusal orthotic for gaining mouth opening amongst OSMF patients would be a beneficial approach. However, it was a single case observation with no control group, so more evidence should be gathered before adopting this approach in practice. Randomised clinical trials are certainly needed to evaluate the role of such therapy.

## Conclusion

Our report is unusual as it demonstrates that an occlusal orthotic can be used in moderate OSMF to increase the mouth opening in a subject with advanced tooth wear.

**Consent:** Written consent was provided by the patient for publishing her case with photograph.

**Disclaimer:** Authors confirm that there is no conflict of interests regarding this case report.

**Conflict of Interest:** None.

**Source of Funding:** None.

## References

- 1- Mehta SB, Banerji S, Millar BJ, Suarez-Feito JM. Current concepts on the management of tooth wear: part 1. Assessment, treatment planning and strategies for the prevention and the passive management of tooth wear. *Br Dent J* 2012;212:17-27. doi: 10.1038/sj.bdj.2011.1099.
- 2- Tiwari B, Ladha K, Lalit A, Dwarakananda Naik B. Occlusal concepts in full mouth rehabilitation: an overview. *J Indian Prosthodont Soc* 2014;14:344-51. doi: 10.1007/s13191-014-0374-y.
- 3- Moshaverinia A, Kar K, Aalam AA, Takanashi K, Kim JW, Chee WW. A multidisciplinary approach for the rehabilitation of a patient with an excessively worn dentition: a clinical report. *J Prosthet Dent* 2014;111:259-63. doi: 10.1016/j.prosdent.2013.11.006.
- 4- Doan PD, Goldstein GR. The use of a diagnostic matrix in the management of the severely worn dentition. *J Prosthodont* 2007;16:277-81. doi: 10.1111/j.1532-849X.2007.00214.x.
- 5- Nam J, Tokutomi H. Using zirconia-based prosthesis in a complete-mouth reconstruction treatment for worn dentition with the altered vertical dimension of occlusion. *J Prosthet Dent* 2015;113:81-5. doi: 10.1016/j.prosdent.2014.08.001.
- 6- Aggarwal V, Singla M. Endodontic management of a patient with oral sub-mucous fibrosis using custom modified endodontic instruments. *J Conserv Dent*. 2012;15:89-91.
- 7- Nigam NK, Aravinda K, Dhillon M, Gupta S, Reddy S, Srinivas Raju M. Prevalence of oral submucous fibrosis among habitual gutkha and areca nut chewers in Moradabad district. *J Oral Biol Craniofac Res* 2014;4:8-13. doi: 10.1016/j.jobcr.2013.10.005
- 8- Richa A, Chandan D, Sumanth P, Ipseeta M. Betel nut chewing and its deleterious effects on oral cavity. *J Cancer Res The* 2014;10:499-505. DOI: 10.4103/0973-1482.137958.
- 9- Gupta SK, Rana AS, Gupta D, Jain G, Kalra P. Unusual causes of reduced mouth opening and it's suitable surgical management: Our experience. *Natl J Maxillofac Surg* 2010;1:86-90. doi: 10.4103/0975-5950.69150.
- 10- Chu FC, Siu AS, Newsome PR, Chow TW, Smales RJ. Restorative management of the worn dentition: 4. Generalized toothwear. *Dent Update* 2002;29:318-24. doi: 10.12968/denu.2002.29.7.318.
- 11- Abduo J, Lyons K. Clinical considerations for increasing occlusal vertical dimension: a review. *Aust Dent J* 2012;57:2-10. doi: 10.1111/j.1834-7819.2011.01640.x
- 12- Thirumurthy VR, Bindhoo YA, Jacob SJ, Kurien A, Limson KS, Vidhiyasagar P. Diagnosis and management of occlusal wear: a case report. *J Indian Prosthodont Soc* 2013;13:366-72. doi: 10.1007/s13191-012-0173-2.
- 13- Williamson EH, Lundquist DO. Anterior guidance: its effect on electromyographic activity of the temporal and masseter muscles. *J Prosthet Dent* 1983;49:816-23. doi: 10.1016/0022-3913(83)90356-6.
- 14- Mahajan AD, Tatu RJ, Shenoy NA, Sharma VS. Surgical management of oral submucous fibrosis in an edentulous patient: A procedural challenge. *Natl J Maxillofac Surg* 2010;1:161-3. doi: 10.4103/0975-5950.79221.
- 15- Dayanarayana U, Doggalli N, Patil K, Shankar J, Mahesh KP, Sanjay. Non surgical approaches in treatment of OSF (ORAL SUBMUCOUS FIBROSIS). *IOSR J Dent Med Sci* 2014;13:63-9. DOI: 10.9790/0853-131136369.
- 16- Kazmi SMR, Khan FR. Orthotic device to maintain or enlarge an oral aperture. United States patent application US 16/990,842. Patent number: US20210378498A1. [Online] 2021 [Cited 2022 December 01]. Available from URL: <https://patents.google.com/patent/US20210378498A1/en>
- 17- Agarwal R, Kaushal A, Singh RK, Upadhyay Y. Management of oral submucous fibrosis by different surgical approaches: report of three cases. *BMJ Case Rep* 2013;2013:bcr2012007871. doi: 10.1136/bcr-2012-007871.
- 18- Kamath VV. Surgical Interventions in Oral Submucous Fibrosis: A Systematic Analysis of the Literature. *J Maxillofac Oral Surg* 2015;14:521-31. doi: 10.1007/s12663-014-0639-3.