

## Ellis-van Creveld syndrome: a case report

Marya Hameed<sup>1</sup>, Ameet Kumar Jesrani<sup>2</sup>, Syed Maaz Tariq<sup>3</sup>, Hina Hanif<sup>4</sup>, Suneeta Bansari<sup>5</sup>, Ashok Kumar<sup>6</sup>

### Abstract

Ellis-van Creveld syndrome (EVC), also known as chondroectodermal dysplasia, is a rare entity. It most commonly affects the tubular bones leading to dwarfism and a long trunk with ossification defects. Other presentations are wide hands and feet, dysplastic nails, thin hair, and cardiac malformations. An eight-year-old female patient presented to our tertiary care centre with complaints of short stature, abnormal dentition, and fatigue. The child's parents were first-degree relatives. On radiological imaging, it was revealed that the patient had postaxial polydactyly, short stature, and genu valgum deformity along with mild cardiomegaly. All these features were indicative of Ellis-van Creveld syndrome. EVC is a rare clinical syndrome with a distinctive clinical presentation. It requires comprehensive radiological investigations and the management is best done with a multidisciplinary approach.

**Keywords:** Cardiomegaly, Polydactyly, Ellis-van Creveld Syndrome.

**DOI:** <https://doi.org/10.47391/JPMA.7049>

### Introduction

Ellis-van Creveld syndrome (EVC) is a rare condition that is inherited in an autosomal recessive pattern. It results from a mutation in two genes which are EVC1 and EVC2 located at locus 16 of chromosome 4 in a classic head-to-head pattern of configuration. This syndrome, which is also termed as chondroectodermal dysplasia in literature, was first described by Richard WB Ellis and Simon van Creveld (1895-1971) of Edinburgh and Amsterdam, respectively.<sup>1</sup> As a matter of coincidence, a greater number of cases were also reported by Mc Kusick in 1964<sup>2</sup> from the Amish community belonging to the US state of Pennsylvania where it is largely prevalent. Cases have also been reported from other races and communities.<sup>3,4</sup> EVC

.....  
<sup>1,3-6</sup>Department of Radiology, National Institute of Child Health, Karachi, Pakistan, <sup>2</sup>Department of Radiology, Sindh Institute of Urology and Transplantation, Karachi, Pakistan.

**Correspondence:** Marya Hameed. Email: drmesh84@gmail.com

**ORCID ID.** >>>>

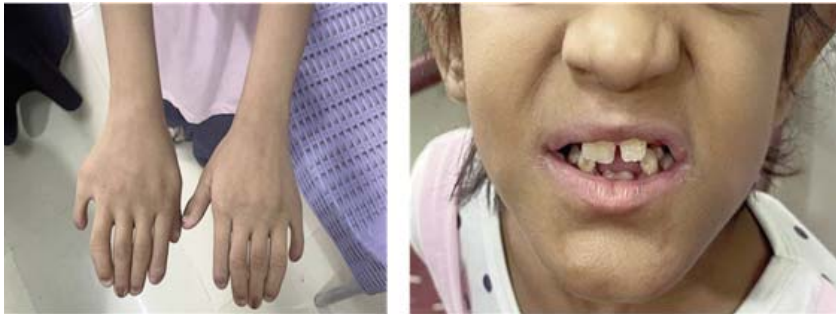**Submission complete:** 16-06-2022 **Review began:** 30-08-2022

**Acceptance:** 11-11-2023 **Review end:** 22-01-2023

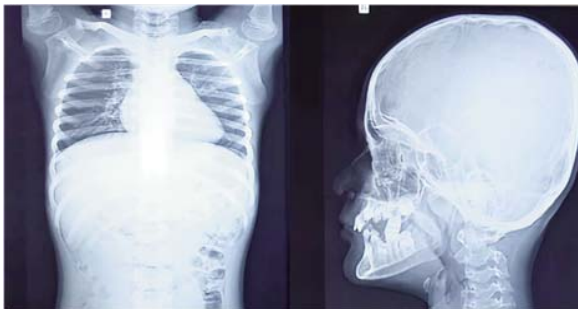
classically presents as a tetrad of physical manifestations: skeletal dysplasia of long bones resulting in patients with short stature and defect in ossification;<sup>5</sup> fingers are usually sausage shaped with wide hands and feet;<sup>6</sup> ectodermal dysplasia, dysplastic nails, oral manifestations; and thin sparse hair.<sup>7</sup> Congenital cardiac malformations are seen in approximately 50%-60% of cases. Most commonly, a single atrium and the ventricular septal defect are observed. The resultant cardiopulmonary problems commonly prove to be lethal in these patients.<sup>4</sup> It is a clinical diagnosis based primarily on observation. A thorough skeletal survey may hold value. The gold standard for diagnosis is looking for homozygous mutations in the EVC and EVC2 genes by employing direct gene sequencing.<sup>8</sup> In this case report, we describe the case of Ellis-van Creveld syndrome reported to the National Institute of Child Health in Karachi, Pakistan.

### Case Report


An eight-year-old female patient reported to the outpatient department at the National Institute of Child Health Karachi with the chief complaint of disproportionate short stature, abnormal dentition (Figure 1), and fatigue. The patient was the eldest child of parents in consanguineous marriage. The medical history of the patient revealed that she experienced dyspnoea while playing in the house for the past year, whereas no significant systemic illness was reported by the parents. The patient had a normal IQ level and was enrolled in a school. The clinical history of the siblings was insignificant. On examination of the hands, it was noted that the patient had dysplastic nails and an extra digit along with the little finger (Figure 1). General physical examination was significant for short height (126cm) (Z score -0.97) along with short limbs and thin body habitus (14 kg) (Z score -2.07), trunk 97cm, and short upper arms with the arm span approximately measuring 101cm. The height minus the arm span was 25 cm. The upper-to-lower body ratio was 3:1. The radiological survey showed disproportionate dwarfism with short limbs signifying mesomelia and a long trunk, polydactyly bilaterally with the sixth digit at the ulnar aspect consistent with bilateral postaxial variety (Figure 3 and Figure 4). The height minus arm span was 25cm. A partial carpal fusion was also identified bilaterally, involving capitate and hamate bone and hypoplastic distal phalanges in both hands. The outer



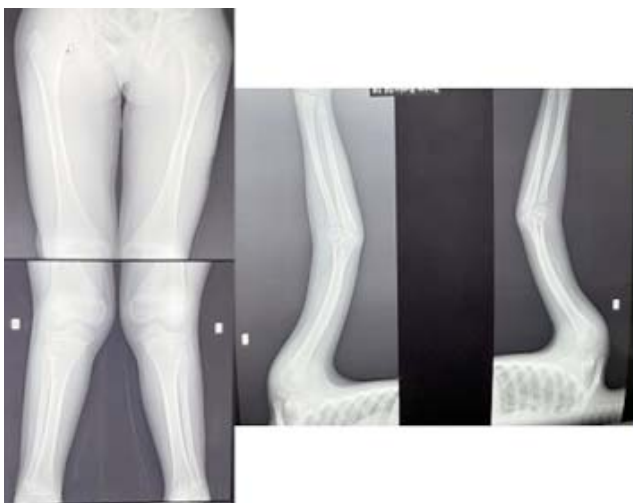
**Figure-1:** Polydactyly on the ulnar aspect and Abnormal growth and placement of teeth.



**Figure-2:** Chest X-Ray significant for cardiomegaly and skull X-Ray significant for abnormal dentition



**Figure-3:** Sixth digit at ulnar aspect consistent with postaxial polydactyly



**Figure-4:** Mesomelic shortening of limbs.

weight-bearing surface of the knee joint showed bilateral lateral plateau depression causing genu valgum deformity. Chest X-ray showed mild cardiomegaly which can be attributed to the narrow thorax in these patients. (Figure 2). Echocardiography showed structural abnormalities. Based on the radiological and clinical findings, the diagnosis of Ellis-van Creveld syndrome was made. Genetic screening could not be performed due to the financial condition of the family and, hence, the diagnosis was established based on hard clinical signs, with consensus among all the authors. An informed consent was taken from the parents before the publication of the case report.

### Discussion

Ellis-van Creveld is a rare skeletal dysplasia which is inherited by an autosomal recessive pattern. It is characterised by short limbs, short ribs, dysplastic nails, and teeth. One of the features of EVC is chondrodystrophy, most commonly affecting the tubular bones.<sup>9</sup> Almost 60% of individuals have a congenital heart defect. Over the last 50 years, less than 50 cases have been described in the literature.<sup>8</sup> Interestingly, it is quite prevalent in the Amish community of Pennsylvania, the US without showing any racial or gender predilection. EVC belongs to the group of short rib polydactyly syndromes which consists of autosomal

recessive disease and have been categorised into different syndromes, namely: 1) Saladino-Noonan syndrome, 2) Majewski syndrome, 3) Verma-Naumoff syndrome, 4) Beemer-Langer syndrome, and 5) Jeune dystrophy.<sup>8</sup> Saladino-Noonan syndrome has narrowed metaphysis; Majewski syndrome has very short ribs, severe pulmonary hypoplasia, and characteristic cleft lip and palate with additional findings of central nervous system abnormalities; Verma Naumoff syndrome has metaphyseal spurs evident on X-ray fining with basal skull shortening; Beemer-Langer syndrome has no polydactyly; Jeune syndrome has a bell-shaped chest and these children usually do not survive past infancy.<sup>10</sup> Therefore, based on the findings, these diagnoses were ruled out in our patient. Consanguinity between parents is a risk factor with the recurrent risk in siblings being 25% for each offspring.<sup>3</sup> The phenotype of EVC is variable as it can

affect a number of organs such as bones, cartilages, teeth, heart, etc. Prenatally, abnormalities can be discovered after the 18th gestational week which include shortening of the long bones, supernumerary digits, and cardiac defects; severe phenotypes are usually an indication to terminate the pregnancy.<sup>11</sup> After birth, the features that come into prominence are disproportionately small stature which increase in severity from proximal to distal limbs, shortened middle to distal phalanges, polydactyly in hands and feet, and ectodermal dysplasia commonly affecting the nails and teeth. The cardiac malformations commonly observed are ventricular septal defect, atrial septal defect, and hypoplastic left heart syndrome. Cardiac abnormalities are considered to be the defining factor for long-term survival.<sup>1,8</sup> The oral presentation of EVC has a wide spectrum which frequently includes labiogingival adherence, gingival hypertrophy, serrated incisal margins, enamel hypoplasia, and premature teeth eruption. Several additional inconsistent findings include hypospadias, and nephrolithiasis.<sup>12,13</sup> The EVC gene can be easily localised by using linkage analysis to the short arm of the 4th chromosome which is the area lying in proximity to other chondrodystrophies. Another gene, EVC2 was also identified as being in a type of head-to-head configuration. A multidisciplinary management is required for EVC. Most symptomatic treatments are needed mainly for respiratory depression which is attributed to the narrow chest and cardiac issues. The teeth of these neonates should be removed because they can potentially cause difficulty in feeding. Dentists also have a huge contribution in the management because of characteristic dental malformations.<sup>8</sup>

## Conclusion

Ellis-van syndrome is an extremely rare clinical phenomenon with even fewer than 50 cases reported in the literature in the last 50 years. It is an autosomal recessive disease that occurs due to a mutation in EVC and EVC2 genes located in chromosome 4 locus 16. We report a case of an eight-year-old female child with classic manifestations of the syndrome such as dysplastic nails, postaxial polydactyly, cardiomegaly, long trunk, short stature, and malformation of teeth. It is a clinical diagnosis with an emphasis on radiological input. The management

is mainly symptomatic and is done best by a multidisciplinary approach.

**Disclaimer:** IRB is signed by one of the co-authors of this manuscript, who is the primary author and also the HoD.

**Conflict of Interest:** None.

**Source of Funding:** None.

## References

- Hills C, Kochilas L, Schimmenti L, Moller J. Ellis-van Creveld Syndrome and Congenital Heart Defects: Presentation of an Additional 32 Cases. *Paediatr Cardiol.* 2011; 32:977-82. doi: 10.1007/s00246-011-0006-9.
- McKusick VA, Hostetler JA, Egeland JA. Genetic studies of the Amish, background and potentialities. *Bull Johns Hopkins.* 1964; 115:203-22. doi: 10.1136/adc.15.82.65.
- Ghassemi M, Goodarzi A, Seirafianpour F, Mozafarpour S, Ziaifar E. Rare clinical features of the Ellis-van Creveld syndrome: A case report and literature review. *Dermatol Ther.* 2021; 34:e14664. doi: 10.1111/dth.14664
- Naqash T, Alshahrani I, Simasetha S. Ellis-van Creveld Syndrome: A Rare Clinical Report of Oral Rehabilitation by Interdisciplinary Approach. *Case Rep Dent.* 2018; 2018:1-5. doi: 10.1155/2018/8631602.
- Krithika CL, Kannan A, Anuradha G, Padmavathi S, Kumar S. Ellis Van Creveld Syndrome: A Case Report. *J Pharm Res Int.* 2021; 28:246-50. doi: 10.9734/jpri/2021/v33i61B35526
- Sergi C, Voigtländer T, Zoubaa S, Hentze S, Meyberg-Solomeyer G, Troeger J, et al. Ellis-van Creveld syndrome: a generalised dysplasia of enchondral ossification. *Paediatr Radiol.* 2001; 31:289-93. doi: 10.1007/s002470000421.
- Zangwill K, Boal D, Ladda R, Opitz J, Reynolds J. Dandy-Walker malformation in Ellis-van Creveld syndrome. *Am J Med Genet.* 1988; 31:123-9. doi: 10.1002/ajmg.1320310114.
- Baujart G, Le Merrer M. Ellis-Van Creveld syndrome. *Orphanet J Rare Dis.* 2007; 2:1-5. doi: 10.1186/1750-1172-2-27
- Goor D, Rotem Y, Friedman A, Neufeld HN. Ellis-van Creveld syndrome in identical twins. *Br Heart J.* 1965; 27: 797-804. DOI: 10.1136/hrt.27.6.797.
- Short-rib polydactyly syndrome. *Obgyn Key.* Online 2018 [Cited 2022 Nov 17]. Available from: URL: <https://obgynkey.com/short-rib-polydactyly-syndrome/>
- Eftekhariyazdi M, Meshkani M, Moslem A, Hakimi P, Safari S, Khaligh A, et al. Ellis van Creveld syndrome: Report of a case and recurrent variant. *J Gene Med.* 2020; 22:e3175. doi: 10.1002/jgm.3175.
- McKusick V. Ellis-van Creveld syndrome and the Amish. *Nat Genet.* 2000; 24:203-4. doi: 10.1038/73389.
- Moudgil A, Bagga A, Kamil E, Rimoin D, Lachman R, Cohen A, et al. Nephronophthisis associated with Ellis-van Creveld syndrome. *Paediatr Nephrol.* 1998; 12:20-2. doi: 10.1007/s004670050395.

## Author's Contributions

**MH and AKJ:** Conception, writing, final approval.

**SMT:** Writing, literature search, final approval.

**HH:** Writing, final approval.

**SB:** Editing, literature search, final approval.

**AK:** Writing, editing, final approval.