

## Usual presentation of an unusual pathogen – *Cryptococcus laurentii* meningitis:

### A case report

Azka Zulfiqar<sup>1</sup>, Rafia Irfan<sup>2</sup>, Faisal Hanif<sup>3</sup>, Javaid Usman<sup>4</sup>

#### Abstract

Infections caused by non-neoformans *Cryptococcus spp.*, including *Cryptococcus laurentii*, previously thought to be saprophyte and non-pathogenic, have become more common during the past few years, particularly in immunocompromised hosts. To the best of our knowledge here, we present the first case of meningitis in an immunocompromised patient due to a fungus that has never been reported in Pakistan. Our patient, a 40-year old male, who had acquired immunodeficiency syndrome (AIDS) was diagnosed as *Cryptococcus laurentii* meningitis, with a rare neurological manifestation i.e., cryptococcomas and lepto-meningitis. We presume that exposure to pigeon droppings and acquired immunodeficiency syndrome were the risk factors for this case report. He was treated with liposomal Amphotericin (LAMB) and fluconazole but unfortunately, he rapidly deteriorated and ultimately succumbed to the infection. This case underscores the significance of prompt diagnosis and vigorous treatment of *Cryptococcus laurentii* meningitis, as well as the need for continued surveillance in immunocompromised individuals.

**Keywords:** Acquired immunodeficiency syndrome, Case report, *Cryptococcus laurentii*, Meningitis.

**DOI:** <https://doi.org/10.47391/JPMA.8582>

**Submission completion date:** 19-09-2022

**Acceptance date:** 27-05-2023

#### Introduction

Cryptococcoses are one of the life-threatening fungal infections worldwide, typically in immunocompromised individuals notably AIDS patients, organ transplant recipients, and those on long-term corticosteroid treatment or chemotherapy.<sup>1</sup> Although the most frequent species of *Cryptococcus* linked to human infections are *Cryptococcus neoformans* and *Cryptococcus gattii* but non-neoformans species which were previously considered to be rare and non-pathogenic, have emerged as an

important source of opportunistic infections in recent years.<sup>1,2</sup> The agents included under this umbrella term are *Cryptococcus albidus*, *Cryptococcus curvatus*, *Cryptococcus humicolus*, *Cryptococcus uniguttulatus* and *Cryptococcus laurentii*.<sup>3</sup>

Kufferath first identified *Cryptococcus laurentii* as *Torula laurentii* in 1920;<sup>4</sup> however, due to changes in its morphology and biochemistry, it was later reclassified as *Cryptococcus laurentii*.<sup>3</sup> Other names for the species include *Trichosporon laurentii* and *Filobasidium laurentii*.<sup>3</sup>

*Cryptococcus laurentii*, an unheard ubiquitous encapsulated yeast-like fungus, most likely to be present in pigeon excrements,<sup>5</sup> has emerged as a significant contributor to cryptococcal illness spectrum ranging from colonization, pneumonia to fungemia and meningitis in an already increasing population of immunocompromised individuals as well as immunocompetent people.<sup>6,7</sup> Although *C. laurentii* infections have comparable clinical symptoms to those brought on by other *Cryptococcus* species, they are typically milder and more confined.<sup>1</sup>

Here we report an unusual case with two manifestations of cryptococcosis i.e., cryptococcomas and lepto-meningitis due to *Cryptococcus laurentii* in an AIDS patient. The purpose of writing this report is to help medical personnel in better understanding of this uncommon but potentially dangerous fungus. Such an unusual fungal infection needs guidelines regarding an early diagnosis and prompt treatment for immunocompromised hosts.

#### Case Report

A 40-year old male, pigeon fancier, presented to the emergency department of Pak Emirates Military Hospital (PEMH), Rawalpindi on 5th April 2022 with a progressively worsening headache that over the past 1 week had become unbearable and was associated with fever and chills. On the day of admission, he vomited thrice and had severe neck pain and photophobia. Family members gave a history of his altered sensorium since the last one day. He had a history of weight loss and generalized weakness since last 6 months.

His vital signs upon presentation were, temperature of 37.4°C, blood pressure 105/70 mm Hg, pulse 100 beats per

<sup>1,2</sup>Department of Microbiology, Army Medical College, National University of Medical Sciences, Rawalpindi, Pakistan; <sup>3,4</sup>Department of Pathology, Army Medical College, National University of Medical Sciences, Rawalpindi, Pakistan.

**Correspondence:** Azka Zulfiqar. e-mail: [azkazulfiqar20@gmail.com](mailto:azkazulfiqar20@gmail.com)  
ORCID ID. 0000-0001-5702-3009

minute, respiratory rate 18 breaths per minute, and an oxygen saturation (SpO<sub>2</sub>) 96%. He was confused and in significant distress. Neurologic examination revealed left facial and hypoglossal nerve palsy, visual neglect, left-sided hemiparesis with increased deep tendon reflexes, a positive Babinski sign, and spasticity. Chest, cardiac and abdominal examination did not reveal any abnormality. His baseline investigations showed neutrophilic leukocytosis. Chest X-ray was unremarkable. Lumbar puncture and contrast-enhanced MRI brain were performed. CE-MRI brain indicated leptomeningitis (Figure 1) and bilateral basal ganglia infarcts with cryptococcoma formation

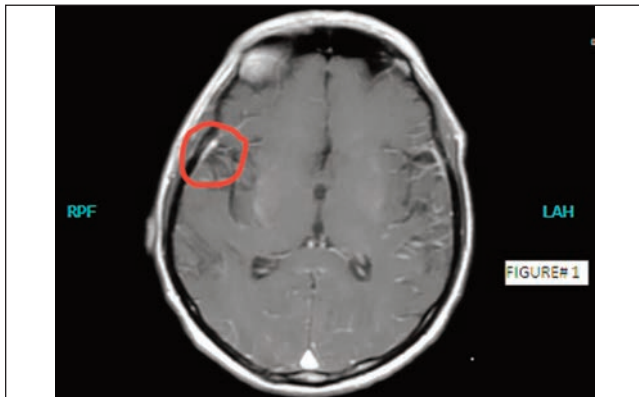


Figure-1: Leptomeningeal enhancement at T1W can be seen.

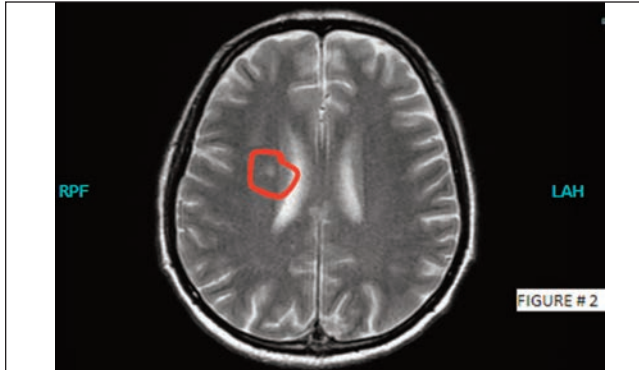

Figure-2: Hyperintense areas seen in right periventricular white matter on T2W.

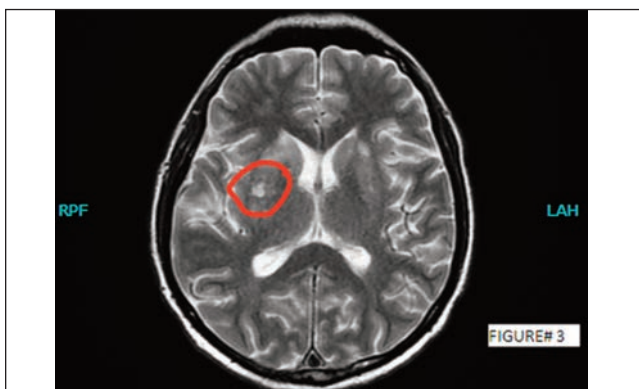

Figure-3: Both basal ganglia demonstrate hyperintense on T2W.

(Figure 2,3). Upon admission his GCS was 12/15 which dropped to 7/15 within a few hours, hence was shifted to the intensive care unit due to his deteriorating condition.

Cerebrospinal fluid routine examination showed raised white blood cell count of 600 cells/ $\mu$ L (0-5 cells/ $\mu$ L) with lymphocytic predominance (80%), decreased cerebrospinal fluid (CSF) glucose 1.3 mmol/L (2.2-3.9 mmol/L), and a raised CSF protein 1200 mg/L (200-450 mg/L). On direct microscopy yeast cells were seen. India ink preparations revealed the presence of encapsulated yeast cells, substantiating the presence of a cryptococcus-like fungus.

CSF was cultured on Sabouraud's agar plate in addition to Blood agar and MacConkey agar plates, which after 48 hours of incubation yielded small mucoid and shiny colonies. On morphology of culture growth, colonies of narrow budding yeast cells were observed. Blood culture also yielded similar growth. *Cryptococcus laurentii* was isolated and identified using the yeast identification system API 20C AUX (BioMérieux). The isolate was applied on VITEK<sup>®</sup> 2 (YST) System (BioMérieux) for further validation, which identified it to be *Cryptococcus laurentii* with 85 % probability in CSF and blood culture samples. Antifungal susceptibility testing (AST) was done by the VITEK<sup>®</sup> 2 (AST-YS08) System. The MIC of Fluconazole was 1  $\mu$ g/ml, Voriconazole  $\leq$ 0.12  $\mu$ g/ml, Caspofungin  $\leq$ 0.12  $\mu$ g/ml, Micafungin  $\leq$ 0.06  $\mu$ g/ml, Amphotericin B  $\leq$ 0.25  $\mu$ g/ml, and of Flucytosine 1  $\mu$ g/ml.

As cryptococcus usually infects hosts with diminished immunity, its isolation in this patient lead to further diagnostic tests. He was found to be infected with HIV with CD4 count of 80 cells/mm<sup>3</sup> and HIV RNA PCR copies of 10070/ml, fulfilling the AIDS defining criteria.

The treating physicians were informed immediately, and they started treatment with Liposomal Amphotericin-B (LAMB) IV at 3 mg/kg/day and Fluconazole 400 mg IV four times a day. Tuberculosis was ruled out to avoid Immune reconstitution inflammatory syndrome (IRIS). Owing to low CD4 count, prophylactic treatment with Co-trimoxazole 800mg/160 mg PO once daily was also started.

Despite antifungals, the patient's condition became critical, and he was put on mechanical ventilation. The patient stayed in ICU for one week and died on 13 April 2022.

## Discussion

Before the AIDS pandemic, cryptococcosis was considered a rare disease. However, it was an eye-opening mycosis in the 1970s after its association with malignancy, organ transplantation, and certain immunosuppressive treatments.<sup>8</sup> In the mid-1980s HIV/AIDS was considered to

account for more than 80-90% cases of cryptococcosis. Although the successful implementation of antiretroviral therapy (ART) has reduced the incidence of disease in developed countries, it's still a problem in other at-risk population.<sup>9</sup> Cryptococcal meningitis is the most common cause of fungal meningoencephalitis worldwide.<sup>10</sup> Cryptococci enter the human body through the inhalation of spores or desiccated yeast cells from the environment.<sup>6</sup> In immunocompromised individuals (including AIDS patients, organ transplant recipients, and those on long-term corticosteroid treatment or chemotherapy), the fungus can spread from the lungs either to the central nervous system, causing meningoencephalitis, or can enter the circulatory system and disseminate haematogenously.<sup>11</sup>

We carried out a comprehensive search for cases reported in the scientific literature using the PubMed database from the year 1980 to 2022 and found 37 cases of *Cryptococcus laurentii* causing meningitis, fungemia, diarrhoea, cutaneous infections, ocular infections, pneumonia, peritonitis, and osteoarthritis in immunocompromised as well as immunocompetent hosts that were isolated in humans worldwide.<sup>1,3,7,8,12</sup> Out of these, 5 reported *Cryptococcus laurentii* meningitis in humans.<sup>8</sup> Only 3 cases of cryptococcal meningitis were reported in AIDS patients from all over the world.<sup>1</sup> Search terms included "infection", "*Cryptococcus*", "*laurentii*", "AIDS", "meningitis". References in each manuscript were reviewed to identify additional cases of *Cryptococcus laurentii* infection.

For this case report, we speculate that exposure to pigeon droppings and AIDS were the risk factors. To the best of our knowledge, this patient is the first case of *Cryptococcus laurentii* meningitis with the coexistence of two rare neurological manifestations cryptococomas and leptomeningitis in an AIDS patient from Pakistan. Being in a low-middle-income country with limited resources, such rare cases are beyond our diagnostic capabilities. The two probable explanations for this isolate being identified as *Cryptococcus laurentii* are his prior exposure to pigeon droppings and our privilege to be having a VITEK® 2 Compact System in our microbiology laboratory. Otherwise finding a yeast fungus like *Cryptococcus* is a rare phenomenon and even when it is seen, it is usually reported as *Cryptococcus neoformans* after an India ink preparation.

## Conclusion

We conclude *Cryptococcus laurentii* as a rare opportunistic pathogen, with first ever case reported from Pakistan, whose isolation is more of an epidemiological and academic interest, with treatment options not being

different from *Cryptococcus neoformans*, however with a low mortality as reported, we expect better outcomes for patients with timely and targeted treatment.

**Consent:** For publication of this case report, consent was obtained from the guardian of the patient.

**Disclaimer:** This case report was presented in "43rd Annual Conference of 'Pakistan Association of Pathologists (PAP)' & '8th Joint Conference of Societies of Pathology'" held on November 25–27, 2022 at Pearl - Continental Hotel, Karachi.

**Conflict of interest:** None.

**Funding disclosure:** None.

## References

- Zhang Y, Cooper B, Gui X, Sherer R, Cao Q. Clinical diversity of invasive cryptococcosis in AIDS patients from central China: report of two cases with review of literature. *BMC Infect Dis.* 2019; 19:1003. doi: 10.1186/s12879-019-4634-7.
- Zhao Y, Ye L, Zhao F, Zhang L, Lu Z, Chu T, et al. *Cryptococcus neoformans*, a global threat to human health. *Infect Dis Poverty.* 2023; 12:20. doi: 10.1186/s40249-023-01073-4.
- Morales-López SE, Garcia-Effron G. Infections due to Rare *Cryptococcus* Species. A Literature Review. *J Fungi.* 2021; 7:279. doi: 10.3390/jof7040279.
- Ferreira-Paim K, Ferreira TB, Andrade-Silva L, Mora DJ, Springer DJ, Heitman J, et al. Phylogenetic Analysis of Phenotypically Characterized *Cryptococcus laurentii* Isolates Reveals High Frequency of Cryptic Species. *PLoS One.* 2014; 9:e108633. doi: 10.1371/journal.pone.0108633.
- Islam N, Bharali R, Talukdar S, Hussain SA, Akand AH, Sarma HK. Occurrence and Distribution of *Cryptococcus* Species in Environmental Sources from Lower Assam Belt of India. *J Pure Appl Microbiol.* 2020; 14:2781-800. <https://doi.org/10.22207/JPAM.14.4.54>
- Huang H, Pan J, Yang W, Lin J, Han Y, Lan K, et al. First case report of *Cryptococcus laurentii* knee infection in a previously healthy patient. *BMC Infect Dis.* 2020; 20:681. doi: 10.1186/s12879-020-05401-z.
- Cano EJ, Yetmar ZA, Razonable RR. *Cryptococcus* Species Other Than *Cryptococcus neoformans* and *Cryptococcus gattii* : Are They Clinically Significant? *Open Forum Infect Dis.* 2020; 7:ofaa527. doi: 10.1093/ofid/ofaa527.
- Ngan NTT, Flower B, Day JN. Treatment of Cryptococcal Meningitis: How Have We Got Here and where are We Going? *Drugs.* 2022; 82:1237-49. doi: 10.1007/s40265-022-01757-5.
- Mei CX, Sun L, Yang K, Min CJ, Zhang L, Yi HX, et al. Cytopathological analysis of bronchoalveolar lavage fluid in patients with and without HIV infection. *BMC Pulm Med.* 2022; 22:55.
- Zono B, Moutschen M, Situakibanza H, Sacheli R, Muendele G, Kabututu P, et al. Comparison of clinical and biological characteristics of HIV-infected patients presenting *Cryptococcus neoformans* versus *C. curvatus*/*C. laurentii* meningitis. *BMC Infect Dis.* 2021; 21:1157. doi: 10.1186/s12879-021-06849-3.
- Bauters TGM, Swinne D, Boekhout T, Noens L, Nelis HJ. Repeated isolation of *Cryptococcus laurentii* from the oropharynx of an immunocompromised patient. *Mycopathologia.* 2002; 153:133-5. Doi: 10.1023/A:1014551200043.
- Londero MR, Zanrosso CD, Corso LL, Michelin L, Soldera J. Catheter-related infection due to *Papiliotrema laurentii* in an oncologic patient: Case report and systematic review. *Braz J Infect Dis.* 2019; 23:451-61.