

## Development of vasogenic cerebral oedema after CT myelogram with nonionic contrast

Meher Angez<sup>1</sup>, Muhammad Sami Alam<sup>2</sup>, Faheemullah Khan<sup>3</sup>, Fatima Mubarak<sup>4</sup>

Madam, Cerebral oedema is fluid accumulation in brain because of a cerebral injury such as trauma, ischaemia, haemorrhage, abscess, tumours, and poisoning. Based on the pathophysiology it is divided into three types cytotoxic, interstitial and vasogenic, among which vasogenic oedema is the commonest type.<sup>1</sup> Vasogenic oedema is a very rare complication of CT myelogram.

A 42-year-old female known case of diabetes, hypertension, focal segmental necrotizing glomerulonephritis, and permanent pacemaker in situ for ASD secundum presented in December 2020 to Aga Khan University Hospital with backache and progressive bilateral lower limb weakness. On clinical examination she was conscious, alert, and oriented. She had a power of 4/5 and +2 reflexes in both the right and left upper limb and a power of 0/5 and absent reflexes in both the lower limbs.

Patient was advised CSF studies and CT myelogram. CT myelogram was performed after a lumbar puncture at L3-L4 level. Approximately 12 mL of non-ionic water-soluble contrast was administered into the spinal canal. CT myelogram was normal. CSF studies showed raised protein.

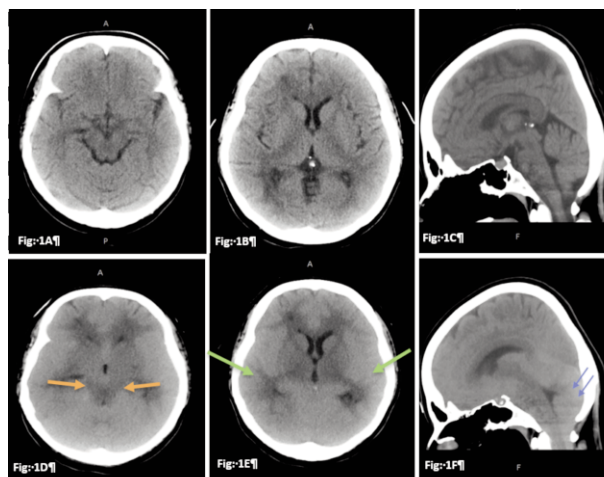
Within less than twelve hours she developed altered sensorium and decreased consciousness. Contrast-enhanced CT brain was performed which showed diffuse effacement of cortical sulci with poor gray-white matter differentiation as shown in Figure 1. There was crowding at the foramen magnum with evidence of tonsillar herniation as shown in Figure 2 and 3. Diagnosis of CT myelogram-induced cerebral oedema was made.

The patient received mannitol along with steroid pulse therapy. There was interval resolution of cerebral oedema

and tonsillar herniation on follow up CT brain (Figure 4 and 5). Endocrinology was taken onboard for the management of her diabetes. Five doses of pulse therapy were given, and after a five-day admission and observation the patient was discharged in stable condition.

CT lumbar myelogram is a well-tolerated commonly performed procedure that employs intrathecal contrast to outline the subarachnoid space. The adverse effects of intrathecal contrast injection include nausea, headache, vomiting, and dizziness due to increase pressure in the subarachnoid spaces. Rare contrast-induced neurotoxicity, status epilepticus seizures and aseptic meningoencephalitis has also been reported with intrathecal and intravascular nonionic contrast agents.<sup>3-5</sup> Cerebral oedema is also a rare complication of intrathecal contrast injection with few case reports being described in the literature.<sup>2</sup>

We are reporting this case so that clinicians are familiar with this uncommon complication of CT myelogram to start early management for better patient outcome.



**Figure:** 1A, 1B & 1C (pre-myelogram) Unenhanced CT head axial and sagittal sections showing patent basal cisterns, sulci, and cerebellar tonsils.

Fig 1D, 1E & 1F (post myelogram) showing effaced basal cisterns (Fig D orange arrow), effaced sulci (Fig E green arrow) with inferior descent of the cerebellar tonsils resulting in tonsillar herniation (Fig F blue arrows)

15th Year MBBS Student, Aga Khan University, Karachi, Pakistan,  
2-4Department of Radiology, Aga Khan University Hospital, Karachi, Pakistan.

**Correspondence:** Fatima Mubarak. Email: fatima.mubarak@aku.edu

**ORCID ID.** 0000-0003-4021-2676

**Submission complete:** 11-03-2023

**Review began:** 10-04-2023

**Acceptance:** 16-08-2023

**Review end:** 05-07-2023

**DOI:** <https://doi.org/10.47391/JPMA.9251>

**Disclaimer:** None.

**Conflict of Interest:** None.

**Source of Funding:** None.

## References

1. Halstead MR, Geocadin RG. The medical management of cerebral edema: past, present, and future therapies. *Neurotherapeutics*. 2019; 16:1133-48. doi: 10.1007/s13311-019-00779-4.
2. Khodor S, Blumenthal S. Vasogenic cerebral edema following CT Myelogram with nonionic Omnipaque 300. *Case Rep Neurol Med*. 2018; 2761872. doi: 10.1016/j.ajem.2011.12.034.
3. Alimohammadi H, Abdalvand A, Safari S, Mazinanian A. Status epilepticus after myelography with iohexol (Omnipaque). *Am J Emerg Med*. 2012; 30:2092-e1. doi: 10.1016/j.ajem.2011.12.034.
4. Singh S, Rajpal C, Nannapneni S, Venkatesh S. Iopamidol myelography-induced seizures. *MedGenMed*. 2005; 7:11.
5. Romesburg J, Ragozzino M. Aseptic meningoencephalitis after iohexol CT myelography. *AJNR Am J Neuroradiol*. 2009; 30:1074-5. doi: 10.3174/ajnr.A1365..

---

## Author's Contributions

**FM and MA:** Conception.

**MA, MSA and FK:** Drafted the manuscript, which was by all the authors.

**All authors** reviewed, edited and approved the final version of the manuscript.